

## Original Article

## Ethanollic Extract of *Nauclea latifolia* (African Peach) Protects Against Ethanol-Induced Gastric Mucosal Injury in Rats

Morufu Eytayo Balogun<sup>1,\*</sup>, Taofeek Olanrewaju Ayinde<sup>2</sup>, Amuda Oluwasola<sup>1</sup>, Akeem Olayinka Busari<sup>3</sup>, Kabiru Adewale Ajibola<sup>3</sup>, Mubarak Muhammad Abubakar<sup>1</sup>

<sup>1</sup>Department of Physiology, Faculty of Health Sciences, Al-Hikmah University Ilorin, Kwara State, Ilorin 240212, Nigeria

<sup>2</sup>Department of Physiology, Faculty of Basic Medical Sciences, University of Ilorin, Kwara State, Ilorin 240003, Nigeria

<sup>3</sup>Department of Medical Laboratory Science, Faculty of Health Sciences, Al-Hikmah University Ilorin, Kwara State, Ilorin 240212, Nigeria

## ARTICLE INFO

## Article history:

Received 29 May 2021

Accepted 10 September 2021

Available online 30 October 2022

## Keywords:

*Nauclea latifolia*

Cytoprotective

Ethanol

Gastric lesions

Rats

## Corresponding author:

Morufu Eytayo Balogun, Ph.D.

Department of Physiology, Faculty of Health Sciences, Al-Hikmah University Ilorin, Kwara State, Nigeria

Phone Number: +2348104031671

Email: marufbalogun755@gmail.com,

mebalogun@alhikmah.edu.ng

Zip code: 240212

## ABSTRACT

**Objective:** *Nauclea latifolia* is widely used in folk medicine in Nigeria and some West African countries. *In vivo* study was conducted to investigate the gastroprotective effects of ethanolic leaf extract of *N. latifolia* (EENL) on ethanol-induced gastric ulcerated rats. **Methods:** Gastric mucosal ulceration was induced experimentally in Groups 2 to 5 rats using ethanol. Five groups of rats were orally pretreated with 3% Tween-80 only as vehicle group, 3% Tween-80 as ulcer group, 20 mg/kg of omeprazole as positive group, 250 and 500 mg/kg of EENL as the test groups, respectively before ulcer induction. Gastric secretion parameters and ulcerated areas were assessed. **Results:** Pretreatment with EENL showed significant ( $P < 0.05$ ) reduction in gastric volume and ulcer index while the pH of gastric content increased significantly ( $P < 0.05$ ) in rats with ethanol-induced ulcer. Ulcer group exhibited significantly severe mucosal injury and EENL or omeprazole offered significant ( $P < 0.05$ ) protection against gastric mucosal ulceration. **Conclusion:** The study suggests that EENL has a protective action against gastric ulcers induced by ethanol in Wistar rats. The protective effect might be mediated via antisecretory and cytoprotective mechanisms.

Please cite this article as: Balogun, M.E., Ayinde, T.O., Oluwasola, A. Busari, A.O. Ajibola, K.A., Abubakar, M.M. (2021). Ethanolic Extract of *Nauclea Latifolia* (African Peach) Protects Against Ethanol-Induced Gastric Mucosal Injury in Rats. *Al-Hikmah Journal of Health Sciences*, 1(1), 22-28.

## Introduction

Gastric ulcer is a major complication of gastrointestinal disease. It is considered a serious health problem that poses economic challenges and thus, has been a subject of many investigations both clinically and experimentally. Globally, gastric ulcer accounts for estimated 15 mortalities out of 15,000 complications annually (Milivojevic and Milosavljevic, 2020). Even though scientists and medical researchers cannot fully ascertain the exact pathogenesis of gastric ulcer, a common ground has

been established. Gastric mucosal ulceration occurred whenever the stomach secretion of aggressive factors (acid and pepsin) overwhelm that of protective factors (mucus and bicarbonate) resulting in disruption of the gastric mucosal layer (Malik *et al.*, 2018). The pathogenesis of gastric ulcer is multifactorial in nature, these include: increased acid-pepsin secretion (Silva and de Sousa 2011), impaired bicarbonate neutralization and reduced mucus secretion (Balogun *et al.*, 2018b). Numerous available orthodox drugs (such as proton pump inhibitors, histamine receptor

antagonists and antibiotics) have been employed in treatment and management of gastric mucosal ulceration. However, the major challenges remain the adverse effects and resistance of these drugs with prolonged use (Alaribe *et al.*, 2014). These triggered the quest for safer and cheaper antiulcer drugs. In view of the above challenges, it is pertinent to investigate the phytotherapy and effectiveness of medicinal plant formulations employed in folkloric medicine for treatment, management and prevention of gastric ulcer. Several medicinal plants used in animal experiments have shown to possess antiulcer effects (Balogun *et al.*, 2015; Iheagwam *et al.*, 2020). *Nauclea latifolia* Smith (*N. latifolia*), commonly known as African peach tree, is an emerging plant of interest in the treatment, prevention and management of gastric ulcer. It is a flowering plant belonging to the family of *Rubiaceae*, and genus of *Sarcocephalus*. It is commonly known as pin cushion tree being a straggling shrub or small tree, native to the tropical Africa and Asia (Udobi *et al.*, 2017).

In Nigeria, it is known locally as “Ubulu inu” among the Igbo in the eastern part of Nigeria; as “Tafashiya” among the Hausas in the northern Nigeria; as “Egbesi” by Yorubas in the western part of Nigeria and as “Itu” among the Itsekiri (Arise *et al.*, 2012; Balogun *et al.*, 2016a). The leaves of *N. latifolia* have many therapeutic applications in folk medicine due to their effective secondary metabolites such as flavonoids, cardiac glycosides, saponin and tannin (Iheagwam *et al.*, 2020). The sticks are used as chewing stick and a remedy against tuberculosis (Balogun *et al.*, 2013; Nyong *et al.*, 2021). There have been scientific documentations on its pharmacological potencies such as hypolipidemic and hypoglycemic, antiulcer, antihypertensive, antioxidative and hepatoprotective effects in animal experiments (Balogun *et al.*, 2015; Onyesom *et al.*, 2015; Oyetayo *et al.*, 2020; Busari *et al.*, 2021). However, despite the acclaimed and documented uses, there appears to be a paucity of information on the gastroprotective activities of ethanolic leaf extract. Therefore, the present study aimed to investigate the gastroprotective possibility of the ethanolic leaf extract of *N. latifolia* (EENL) on ethanol-induced ulcerated rats.

## Materials and Methods

### Drug and reagents

Drug, chemicals, and reagents used in this study were obtained commercially and of analytical grade. Tween 80, ethanol, diethyl ether, HCl and NaOH were procured from Sigma-Aldrich Chemical Company (St. Louis Missouri, USA). Distilled water was obtained from Physiology Laboratory, Al-Hikmah University, Ilorin, Nigeria.

### Drug preparation

Omeprazole (Globela Pharma PVT. Ltd., India), purchased from One Step Pharmacy, Ilorin, Nigeria, was used as reference antiulcer drug in this study. The drug was dissolved in 3% Tween-80 and administered to the animals orally in a dose of 20 mg/kg body weight (5 mL/kg) prior to gastric ulcer induction as earlier described by Balogun *et al.*, (2018a).

### Experimental animals

Healthy adult male (9-10 weeks old) Wistar rats weighing ( $178.30 \pm 5.92$ ) g were used for the study. The rats were obtained from the Faculty of Health Sciences, Central Animal House, Al-Hikmah University, Ilorin. They were kept under standard laboratory conditions and fed with commercial grower's feed (Vital feeds Nig Ltd, Nigeria) and water *ad libitum*. The animals were allowed one-week acclimatization before the experiment commenced.

### Ethics statement

The research was conducted following the approval by the ethics committee for animal experimentation of the Faculty of Health Sciences, Al-Hikmah University, Ilorin (Ethic No. HUI/REC/FHS/2021/02) and animal handling was according to accepted guidelines by the National Institutes of Health for care and use of laboratory animals (NRC, 2010).

### Collection and authentication of plant material

Fresh leaves of *N. latifolia* were collected from a farm settlement in Iseyin Local Government Area of Oyo State, Nigeria. The leaves were identified and authenticated by Mr. K.A. Adeniji of the Forestry Research Institute of Nigeria (FRIN) Ibadan, Nigeria. A voucher specimen (FHI. 110284) was deposited in the herbarium of the institute for future references.

### Preparation of ethanolic leaf extract

Freshly collected leaves were thoroughly washed with distilled water and air dried at room temperature. The leaf powder (1200 g) was extracted with absolute ethanol (96%, v/v) in a soxhlet extractor at 70°C. The mixture was vacuum-filtered through Whatman No. 1 filter paper and the filtered extract was concentrated using a vacuum rotary evaporator (Eyla N-1000, Japan) maintained at 45°C. The resulting residue which weighed 98.6 g (recovery 8.2%) was later stored under 4°C before use. Prior to oral administration of the extract, the required dose of 250 or 500 mg/kg body weight was obtained after the extract was reconstituted in 3% Tween-80 (Balogun *et al.*, 2018b; Iheagwam *et al.*, 2020).

**Preliminary phytochemical analysis**

The EENL was subjected to qualitative phytochemical screening to pinpoint the presence of secondary constituents (such as alkaloids, saponins, terpenoids, glycosides, anthraquinones, flavonoids, tannins, resins, cardiac glycosides, steroids and phenols) using standard phytochemical methods described by Harborne, (1988).

**Acute oral toxicity studies**

The “fixed dose” method of Organization for Economic Cooperation and Development (2008) guideline No. 425 was employed to determine the acute oral toxicity of EENL in adult albino rats (OECD, 2008). The method was commenced with an initial dose of 2000 mg/kg body weight after overnight dietary deprivation. The animals were observed for general behavioural, autonomic and neurological behaviour during the course of the experiment.

**Experimental design and treatment**

Gastric mucosal injury was induced experimentally in groups 2 to 5 using ethanol. The rats were allotted into five groups of five rats in each group. Group 1 (normal control) received 3% Tween-80 only. Group 2 (ulcer control) received 3% Tween-80. Group 3 (standard) received 20 mg/kg omeprazole while groups 4 and 5 (test groups) received 250 and 500 mg/kg body weight (5 mL/kg body weight) of EENL respectively. The administration was done by oral gavage for all groups prior to ulcer induction.

**Ethanol-induced gastric ulcer**

Gastric mucosal ulceration was induced experimentally using ethanol-induced model previously described by Mizui and Douteuchi (1983). In this method, gastric lesion was induced in 24 h fasted rats by the oral administration of 1 mL/kg of ethanol (80% ethanol) 30 min after 3% Tween-80, omeprazole (20 mg/kg body weight), EENL (250 and 500 mg/kg body weight) were administered.

**Excision of stomach and gastric juice collection**

The rats were sacrificed humanely under diethyl ether (Sigma-Aldrich, USA) anaesthetization after 1 h of ethanol administration. The stomach was excised and opened along the greater curvature following the opening of the abdomen. The gastric content of the stomach was drained into a centrifuge tube in addition with 5 mL of distilled water. The resultant solution was centrifuged at  $3000 \times g$  for 10 min at 4 °C and the supernatant collected was subjected to biochemical analyses thereafter (Shay *et al.*, 1954).

**Ulcer score and percentage inhibition**

The gastric mucosal layer of the stomach was viewed under a magnifying lens (x10) to evaluate the gastric lesions. The number of ulcers were counted and scored using the method described by Kulkarni *et al.*, (1987). The score was graded as 0, normal colouration; 0.5, red colouration; 1.0, spot ulcers; 1.5, haemorrhagic streaks; 2.0, deep ulcers; 3.0, perforations. The sum of ulcer scores assigned to gastric lesions was expressed as the mean ulcer index (MUI) (Tan *et al.*, 1996). Percentage of ulcer inhibition was calculated according to Hojage *et al.* (2010) using the formula: Percentage inhibition (%I) =  $(MUI_{\text{control}} - MUI_{\text{test}}) \div MUI_{\text{control}} \times 100\%$

**Determination of gastric juice volume and pH**

The supernatant fluid volume was measured in millilitre (mL) using micro syringe (Bickel and Herling, 2002). The gastric content samples were analysed for hydrogen ion concentration using a digital pH meter (Abdulla *et al.*, 2010).

**Gross evaluation of gastric mucosa**

The mucosal layer of the stomach of each rat was rinsed with normal saline to remove blood clot if any. The stomach was then pinned to a flat board to observe any changes in the physical appearance of the mucosa. Photographs of the gastric lesions were taken for proper observation and documentation.

**Statistical analysis**

The values were expressed as mean  $\pm$  standard error of mean. For data comparison, one-way analysis of variance (ANOVA) was used followed by Tukey's multiple comparison tests. Differences between groups were considered statistically significant at  $P < 0.05$  using Graph pad Prism Version 6.0 for Windows (GraphPad® Software, San Diego, CA, USA).

**Results****Extract yield**

The ethanolic extraction of 1200 g of *N. latifolia* leaf powder yielded 8.2% (w/w) greenish semisolid extract with a paste consistency.

**Qualitative phytochemical analysis**

The result of the preliminary qualitative phytochemical studies of EENL showed the presence of saponins, tannins, cardiac glycosides, alkaloids, flavonoids, terpenoids and phenols.

**Acute oral toxicity studies**

All the animals remained alive and showed no visible signs of toxicity even with the highest dose. There were no abnormal signs, changes in body weight and behaviour in the EENL-treated animals throughout the

observation period when compared to normal control animals. Thus, the median lethal dose was considered to be greater than 2000 mg/kg body weight.

#### Effect of EENL on ulcer index and ulcer inhibition

The effects of EENL on ulcer index and inhibition are reported in Table 1. Ulcer index in the ulcer control group was significantly ( $P < 0.05$ ) increased as

compared to compared normal control group. The severity of ethanol-induced gastric ulcer was significantly ( $P < 0.05$ ) reduced by pretreatment with EENL (250 and 500mg/kg) or omeprazole. The extract exhibited a dose-dependent inhibition against ulceration in rats. However, maximum inhibition was observed in omeprazole pretreated group, which was similar to the 500 mg/kg EENL.

**Table 1:** Effects of EENL on ulcer index and ulcer inhibition in ethanol-induced ulcerated rats

Group	Treatment and dose	Ulcer index	Ulcer inhibition (%)
1 (Normal control)	Tween 80 (2 mL/kg)	0.00 ± 0.00	100.00
2 (Ulcer control)	Tween 80 (2 mL/kg) + ethanol (1 mL/kg)	16.70 ± 1.67 <sup>a</sup>	0.00
3 (Standard)	Omeprazole (20 mg/kg) + ethanol (1 mL/kg)	1.40 ± 0.89 <sup>b</sup>	91.6
4 (Experimental)	EENL (250 mg/kg) + ethanol (1 mL/kg)	2.10 ± 0.94 <sup>b</sup>	87.4
5 (Experimental)	EENL (500 mL/kg) + ethanol (1 mL/kg)	1.70 ± 1.75 <sup>b</sup>	89.8

All values are expressed as mean ± standard error of mean (n = 5 in each group). <sup>a</sup> $P < 0.05$ , vs normal control group; <sup>b</sup> $P < 0.05$ , vs ulcer control group. EENL: ethanolic leaf extract of *Nauclea latifolia*.

#### Effect of EENL on gastric juice content and pH

The effects of EENL on gastric juice volume and pH are reported in Table 2. The gastric juice volume was significantly increased ( $P < 0.05$ ) in the ulcer control group with concomitant decrease in pH when compared to the normal control group. The group pretreated with 250 mg/kg or 500mg/kg EENL

produced a significant decrease ( $P < 0.05$ ) in gastric juice volume with corresponding increase in pH compared to the ulcer control group. Meanwhile, a significant ( $P < 0.05$ ) decrease in gastric volume with concomitant increase in pH was observed in groups pretreated with omeprazole (20 mg/kg) in comparison to the ulcer control group.

**Table 2:** Effects of EENL on gastric juice volume and pH in ethanol-induced ulcerated rats

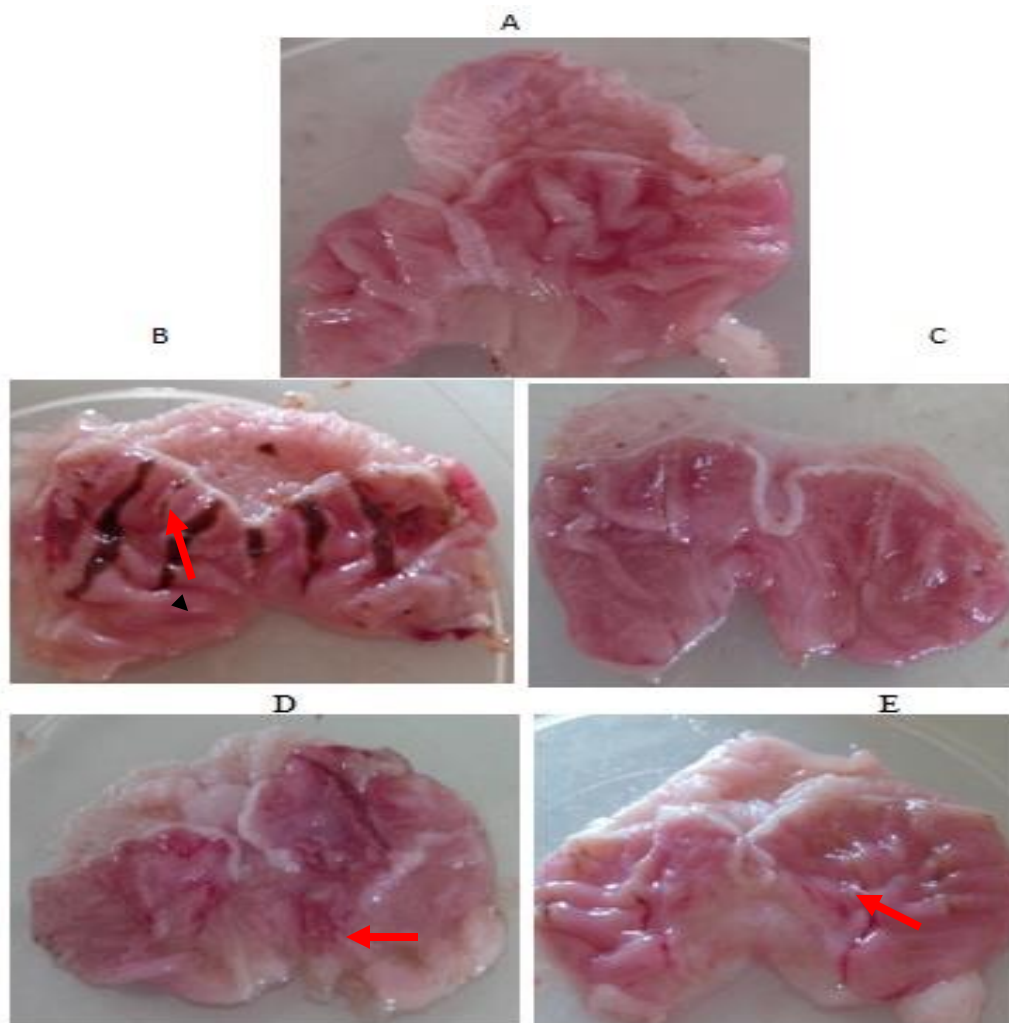
Group	Treatment and dose	Gastric content (mL)	pH
1 (Normal control)	Tween 80 (2 mL/kg)	7.43 ± 0.25	3.54 ± 0.49
2 (Ulcer control)	Tween 80 (2 mL/kg) + ethanol (1 mL/kg)	10.08 ± 0.67 <sup>*</sup>	1.48 ± 0.33 <sup>*</sup>
3 (Standard)	Omeprazole (20 mg/kg) + ethanol (1 mL/kg)	4.57 ± 0.89 <sup>#</sup>	5.97 ± 0.75
4 (Test)	EENL (250 mg/kg) + ethanol (1 mL/kg)	5.04 ± 0.96 <sup>#</sup>	5.09 ± 0.86 <sup>#</sup>
5 (Test)	EENL (500 mL/kg) + ethanol (1 mL/kg)	4.89 ± 1.75 <sup>#</sup>	5.63 ± 0.07 <sup>#</sup>

All values are expressed as mean ± standard error of mean (n = 5 in each group). <sup>\*</sup> $P < 0.05$ , vs normal control group; <sup>#</sup> $P < 0.05$ , vs ulcer control group; EENL: ethanolic leaf extract of *Nauclea latifolia*.

#### Effects of EENL on macroscopic appearance of the gastric mucosa

In Fig. 1, the vehicle control group showed normal gastric mucosal architecture. Ulcer control group showed severe gastric mucosal injuries with extensive

haemorrhagic necrosis of the gastric mucosa (red arrow). EENL-pretreated groups (250 and 500 mg/kg) exhibited a fairly protected mucosa in ethanol-induced ulcer model compared to the injuries seen in the ulcer control rats.



**Fig. 1:** Gross appearance of the gastric mucosa in ethanol-induced ulcerated rats. A: Vehicle control group; B: Ulcer control group; C: Omeprazole group; D: EENL (250mg/kg) group; E: EENL (500mg/kg) group. Red arrows point to the gastric mucosal injuries. EENL: ethanolic leaf extract of *Nauclea latifolia*.

### Discussion

In recent times, the identification and evaluation of drugs from natural products as an alternative therapeutic approach in the prevention and management of gastrointestinal diseases including gastric ulcer is on the increase. The current study was designed to investigate the possible gastroprotective effects of ethanolic leaf extract of *N. latifolia* (EENL) using ethanol-induced ulcer model. Based on the available research data, the study has demonstrated that EENL possessed significant gastroprotective activity against ethanol-induced gastric ulceration in rats. The extract at low and high doses offered 87.4% and 89.8% mucosal protection respectively against ethanol-induced ulcerations. It is interesting to note that the extract at both doses, showed an increase in gastric pH with concomitant decrease in gastric juice

volume similar to omeprazole. However, the mechanisms behind these gastroprotective effects of EENL in rats have not yet been ascertained. The pathogenic effects of ethanol-induced lesions have been established to include increased secretion of gastric acid, which resulted in increased gastric volume, reduced pH, and increased in ulcer index (Malik, 2018). Findings from this study show that in ethanol model, the EENL (250 and 500 mg/kg) pretreated groups produced a significant decrease in the gastric volume content with a corresponding increase in pH compared to the ulcer control group. This decrease in gastric juice volume in the extract pretreated groups may be due to a decrease in gastric acid production as evidenced from the gastric juice pH. From this study, the results showed that EENL can significantly prevent the gastric effects of ethanol by



exhibiting a fairly protected mucosa with a significant decrease in ulcer index in comparison to the ulcer control group. Several reports both *in vitro* (Boucherle *et al.*, 2016) and *in vivo* (Busari *et al.*, 2021) have shown that *N. latifolia* leaf extracts have a potent antioxidant effect. Large amounts of antioxidant compounds have been reported to be present in the leaves of *N. latifolia* (Onyesom *et al.*, 2015; Iheagwam *et al.*, 2020). The active compounds flavonoids and cardiac glycosides which are present in the leaves have been reported by Akinwunmi *et al.* (2019) and Balogun *et al.*, (2015) as antioxidant materials. However, it is presumed that the gastroprotective activity of this extract could be attributed to its antisecretory potential which offers a first line of defence against any ulcerogenic agent by bolstering the mucosal defence system. Ethanolic leaf extract of *N. latifolia* has been shown to contain phytochemicals such as flavonoids, cardiac glycosides and terpenoids which are among the cytoprotective materials known to possess antioxidant activities (Balogun *et al.*, 2013; Oyetayo *et al.*, 2020) which is in agreement with our findings. Therefore, it is pertinent that the decrease in gastric lesions, decrease in volume and increase in gastric juice pH produced by EENL in this study could be due to the presence of these active components or some other mechanisms yet to be unravelled. Hence, further studies are required to establish the exact mechanism of action and isolate the active ingredients in the leaves responsible for the observed gastroprotective effects so as to provide new alternatives for the clinical management of gastric ulcers. In conclusion, the study suggests that EENL possesses significant gastroprotective effects against ethanol-induced gastric ulcer in rats. The observed gastroprotective effect might be due to its antisecretory and cytoprotective activities. Our results may have beneficial application in the management of gastric mucosal lesions associated with ethanol-induced gastric mucosal ulceration.

### Competing interests

The authors declare no conflict of interest.

### Acknowledgments

The authors are thankful to Professor Noah Yusuf, Vice-Chancellor, Al-Hikmah University Ilorin, for providing necessary facilities and encouraging our research works.

### References

Abdulla, M. A., Al-Bayat, F. H., Younis, L. T., & Abu Hassan, M. I. (2010). Anti-ulcer activity of *Centella asiatica* leaf extract against ethanol-induced gastric mucosal injury in rats. *J Med Plants Res*, 4(13), 1253-1259.

Akinwunmi, O. A., Olatunde, O. C., & Adefemi, S. (2019). Preliminary investigation of *Nauclea latifolia* ripe fruits for antioxidant and antidiabetic activities. *Journal of Applied and Natural Science*, 11(3), 718-723.

Alaribe, C. S., Adesegun, S., Idowu, A. O., Egere, O., Ihemedu, C., Coker, H. A. B., & Smith, S. (2014). Healing, cytoprotective and anti-*Helicobacter pylori* activities of stem bark extracts and butanol fraction of *Nauclea latifolia*. *J Nat Prod*, 7, 184-195.

Balogun, M. E., Besong, E. E., Obimma, J. N., Djibissie, S. F., & Mbamalu, O. S. (2018a). Gastroprotective effect of ethanolic extract of *Vigna subterranea* in ethanol-induced gastric mucosal ulceration in Rats. *Indian Journal Physiology and Pharmacology*, 62, 347-358.

Balogun, M. E., Besong, E. E., Obimma, J. N., Mbamalu, O. S., & Djibissie, F. S. A. (2018b). Protective roles of *Vigna subterranea* (Bambara nut) in rats with aspirin-induced gastric mucosal injury. *Journal of integrative medicine*, 16(5), 342-349.

Balogun, M. E., Besong, E. E., Obu, D. C., Obu, M. S. U., & Djibissie, S. F. A. (2016a). *Nauclea latifolia*: A Medicinal, Economic and Pharmacological Review. *International Journal of Plant Research*, 6(2): 34-52

Balogun, M. E., Jeje, S. O., Salami, S. A., Onwe, P. E., & Folawiyo, M. A. (2015). Anti-ulcerogenic and gastric anti-secretory effects of *Nauclea latifolia* extract in male albino rats. *European Journal of Experimental Biology*, 5, 74-80.

Balogun, M. E., Nwachukwu, D. C., Salami, S. A., Besong, E. E., Obu, D. C., & Djibissie, S. F. A. (2016b). Assessment of anti-ulcer efficacy of stem bark extract of *Nauclea latifolia* (African peach) in rats. *America Journal of Biomedical Research*, 4(1), 13-7.

Balogun, M. E., Oji, J. O., Besong, E. E., Ajah, A. A., & Michael, E. M. (2013). Anti-ulcer activity of aqueous leaf extract of *Nauclea latifolia* (rubiaceae) on indomethacin-induced gastric ulcer in rats. *African Journal of Biotechnology*, 12(32).

Bickel, M., & Herling, A. W. (2002). Activity on the gastrointestinal tract. *Handbook of Drug Discovery: Pharmacological Assays*, 1191-1322.

Boucherle, B., Haudecoeur, R., Queiroz, E. F., De Waard, M., Wolfender, J. L., Robins, R. J., & Boumendjel, A. (2016). *Nauclea latifolia*: biological activity and alkaloid phytochemistry of a West African tree. *Natural product reports*, 33(9), 1034-1043.

Busari, M. B., Hamzah, R. U., Muhammad, H. L., Yusuf, R. S., Madaki, F. M., Adeniyi, J. O., ... &

- Berinyuy, E. B. (2021). Phenolic rich-extracts from *Nauclea latifolia* fruit restored Lead acetate-induced liver and kidney damaged in Wistar rats. *Clinical Phytoscience*, 7(1), 1-10.
- Gerhard, V. H. (2002). Activity on gastrointestinal tract. *Drug Discovery and Evaluation: Pharmacological Assays*, 944.
- Harborne, A. J. (1998). *Phytochemical methods a guide to modern techniques of plant analysis*. springer science & business media.
- Hojage, M. G., Hriprassanna, R., Patil, K., Matha Pati, S., Wadkar, G., & Rao, K. P. (2010). Anti-ulcer effects of alcoholic extracts of *Murus Alba* Linn leaves in rodents. *Indian Drugs*, 47(6), 64-68.
- Iheagwam, F. N., Israel, E. N., Kayode, K. O., DeCampos, O. C., Ogunlana, O. O., & Chinedu, S. N. (2020). *Nauclea latifolia* Sm. Leaf extracts extenuates free radicals, inflammation, and diabetes-linked enzymes. *Oxidative Medicine and Cellular Longevity*, 2020.
- Kulkarni, S. K. (1987). *Hand book of experimental pharmacology*. Vallabh prakashan.
- Malik, T. F., Gnanapandithan, K., & Singh, K. (2018). Peptic ulcer disease.
- Milivojevic, V., & Milosavljevic, T. (2020). Burden of gastroduodenal diseases from the global perspective. *Current Treatment Options in Gastroenterology*, 18(1), 148-157.
- Mizui, T., & Doteuchi, M. (1983). Effect of polyamines on acidified ethanol-induced gastric lesions in rats. *Japanese Journal of Pharmacology*, 33(5), 939-945.
- National Research Council. (2010). Guide for the care and use of laboratory animals.
- Nyong, B. E., Etim, A. N., Ita, P. O., & Ucheokoro, A. S. (2021). Antimicrobial properties of alcoholic extract of African Peach (*Nauclea latifolia*) leaves. *International Journal of Current Research in Medical Sciences*, 7(9), 1-7.
- Onyesom, I., Osioma, E., & Okereke, P. C. (2015). *Nauclea latifolia* aqueous leaf extract eliminates hepatic and cerebral *Plasmodium berghei* parasite in experimental mice. *Asian Pacific Journal of Tropical Biomedicine*, 5(7), 546-551.
- Organization for Economic Cooperation and Development (2008). OECD guidelines for testing of chemicals, Section 4; Test No. 425: acute oral toxicity—up-and-down procedure.
- Oyetayo, F. L., Oseni, O. A., Akinlolu, O. S., & Uwaremhevho, D. (2020). Antidiabetic, Antilipidemic and Antioxidant Properties of Aqueous Extracts of *Morinda Lucida* and *Nauclea Latifolia* Leaves in Alloxan Induced Rats.
- Shay, H., Sun, D. C., & Gruenstein, M. (1954). A quantitative method for measuring spontaneous gastric secretion in the rat. *Gastroenterology*, 26(6), 906-913.
- Silva, M. I. G., & de Sousa, F. F. (2011). Gastric ulcer etiology. *Peptic ulcer disease*, 1.
- Tan, P. V., Nditafon, N. G., Yewah, M. P., Dimo, T., & Ayafor, F. J. (1996). *Eremomastax speciosa*: effects of leaf aqueous extract on ulcer formation and gastric secretion in rats. *Journal of Ethnopharmacology*, 54(2-3), 139-142.
- Udobi, C., Umoh, B., & Asuquo, E. G. (2017). Effects of the ethanol extract of the stem bark of *Nauclea latifolia* Smith [Rubiaceae] on certain biochemical and haematological indices of Swiss Albino Mice. *Asian Journal of Medicine and Health*, 6(1), 1-9.